



## LIVER HISTOPATHOLOGY OF MICE INDUCED BY PARACETAMOL ON ADMINISTRATION OF METHANOL EXTRACT OF LABAN TREE BARK (*Vitex pubescens* Vahl.)

Wiwit Anggraini, Diah Wulandari Rousdy\*, Elvi Rusmiyanto Pancaning Wardoyo

Biology Departement, Faculty Mathematics and Natural Sciences, University of Tanjungpura  
Jl. Prof. Dr. H. Hadari Nawawi, Pontianak, West Kalimantan, Indonesia 78124

\*Corresponding author: [diah.wulandari.rousdy@fmipa.untan.ac.id](mailto:diah.wulandari.rousdy@fmipa.untan.ac.id)

### ARTICLE INFO

#### Article history

Submission 2022-04-04  
Revision 2022-08-05  
Accepted 2023-04-09

#### Keywords:

Liver histopathology  
Mice  
Paracetamol  
*Vitex pubescens* Vahl.

### ABSTRACT

Paracetamol metabolism takes place in the liver mediated by CYP450 enzymes and generates NAPQI radicals. The NAPQI radical is highly electrophilic to hepatocyte biomolecules and is therefore capable of inducing liver damage. Laban tree bark (*V. pubescens*) methanol extract is known to contain antioxidant compounds of flavonoids, saponins, and tannins with an IC<sub>50</sub> value of 19.83 g/ml. This study aims to determine the optimal dose of extract that can improve the liver microanatomy of mice induced by a toxic dose of paracetamol (TDP). This study used 30 male Swiss strain mice with a body weight of 20-30 g. The treatments given consisted of negative control (paracetamol 105 mg kg<sup>-1</sup>), positive control (vitamin E 46.8 mg kg<sup>-1</sup>), and laban extract at a dose of 75; 150; 300; 600 mg kg<sup>-1</sup> BW. Liver microanatomy parameters measured included hepatocyte diameter (19.50±0.21 μm), sinusoids (4.39±0.23 μm), and central vein (36.84 ± 1.79 μm). Data were analyzed using one-way ANOVA and Duncan's Multiple Range Test further tests were then presented in the form of mean ± standard deviation. The results showed that extract at a dose of 600 mg kg<sup>-1</sup> had hepatocyte, sinusoid, and central vein diameters that were not significantly different ( $p > 0.05$ ) from vitamin E.

## INTRODUCTION

The liver is rich in metabolic enzymes so its functions of biotransformation and detoxification are more significant than other body organs. In certain cases, the biotransformation process can produce compounds that are more toxic than the original compounds. Therefore, the liver is susceptible to damage as an impact of exposure to hepatotoxic metabolites, such as paracetamol. According to Katzung (2014) and Wilmana & Gan (2012), there are approximately 80% of paracetamol in the body will be conjugated

with glucuronic acid and sulfuric acid through the glucuronidation and the sulfate pathways to become inactive metabolites that are more polar so that they are easy to be excreted with urine. The radicals of NAPQI (N-Acetyl-1,4-Benzoquinone Imine) will be formed when the glucuronidation pathway is saturated so that paracetamol will be oxidized by the CYP450 enzyme (cytochrome P450).

The radicals of NAPQI in the liver will be neutralized by nucleophiles in the liver, namely the antioxidant glutathione. The thiol group (-SH) in glutathione binds covalently to the NAPQI radicals and then undergoes metabolism and becomes mercapturic acid which will be eliminated through the kidneys. In the case of paracetamol toxicity, the body experiences glutathione antioxidant depletion so that the NAPQI radicals will oxidize hepatocyte biomolecules such as membrane lipids, proteins, as well as hepatocyte genetic materials. This peroxidation causes mild injury (degeneration) to hepatocyte necrosis (Bunchorntavakul & Reddy, 2013).

Liver damage due to paracetamol overdose can be prevented by giving natural antioxidant compounds. Laban plant (*Vitex pubescens* Vahl.) is a member of the genus *Vitex* which is used in traditional medicine. The secondary metabolites of flavonoids, tannins, and saponins are found in the methanol extract of laban bark. The test results of DPPH (1,1-Diphenyl-2-Pikrihidrazil) of methanol extract of laban bark showed an IC50 value of 19.83 µg/ml or categorized as a very strong antioxidant (Hermansyah *et al.*, 2015; Jun *et al.*, 2003).

The leaves and bark of Laban have been used as traditional medicine by the Dayak Pangkodan tribe of West Kalimantan and the Dayak Tunjung community of East Kalimantan as a tea beverage which is believed to be able to cure diarrhoea, dysentery and malaria (Adelina *et al.*, 2010). This is the background for further research regarding the potential of methanol extract of laban bark as a hepatoprotector. This study aims to find out the optimal dose of methanol extract of laban bark which can repair mice liver damage induced by paracetamol toxic doses.

## **MATERIALS AND METHODS**

### ***Place dan Date***

This research was carried out from February to September 2020 at the Zoology Laboratory, Faculty of Mathematics and Natural Sciences, Tanjungpura University.

### ***Research Animals***

This study used 30 male mice (*Mus musculus* L.) Swiss strain 2-3 months old and body weight of 25-30 g. Acclimation of mice was carried out for 7 days with feeding and drinking *ad libitum* (Garber *et al.*, 2011).

### ***Research Protocol***

The study design used a completely randomized design (CRD). The treatment was given in the form of oral induction of a toxic dose of paracetamol (PDT) on days 1-7 then followed by giving *V. pubescens* bark extract on days 8-14. The treatments consisted of negative control (PDT 105 mg kg<sup>-1</sup> BW), positive control (vitamin E 46.8 mg kg<sup>-1</sup> BW), and 4 doses of extract 75; 150; 300; 600 mg kg<sup>-1</sup> BW.

### ***Laban Bark Extraction***

Laban (*V. pubescens*) bark samples as much as 2 kg were taken from the district of South Pontianak, West Kalimantan. The samples were washed with running water and cut into small pieces, then dried. The sample was crushed to become a powder. Simplicia powder was immersed in methanol solvent at room temperature. Stirring is done several times to complete the transfer of chemical components into the solvent (Voigh, 1995). Then, the macerate solution was filtered through filter paper to obtain a clear solution (Wulandari *et al.*, 2018). The macerate was concentrated using a rotatory evaporator to obtain a thick extract (Hermasyah *et al.*, 2016).

### ***Preparation of Liver Histology***

After the 14<sup>th</sup> day of treatment, the mice were anaesthetized with chloroform and terminated immediately using surgical blades. The liver was taken and washed with 0.9% NaCl solution. Liver preparations were made using the paraffin method and staining with the hematoxylin-eosin method (Suvarna *et al.*, 2013). Liver organs were cut to 3-5 mm in size using a razor blade and fixed in 10% Buffer Neutral Formaline (BNF) for 12 hours. Liver organs were dehydrated in graded alcohol starting from a concentration of 70% for 4×30 minutes, 80% alcohol for 3×30 minutes, 90% alcohol for 3×30 minutes, 96% alcohol for 2×30 minutes, and 100% alcohol for 2×30 minutes. Clearing organ in xylol for 15-20 minutes, infiltrated in paraffin: xylol (1:1) for 50 minutes and in pure paraffin for 3×50 minutes. Infiltration was carried out in an oven at 58-60 °C. Organs were embedded in paraffin blocks and sliced at 6 μm thickness with a rotary microtome. The

paraffin section was stained using hematoxylin-eosin. Liver microanatomy was observed with a light microscope and ImageJ application at a magnification of 400× for 5 microscopic fields of view (Makiyah & Khumaisah, 2018).

### **Data Analyze**

The microanatomical parameters of the liver that were measured included hepatocyte diameter, sinusoids, and central vein. The measurement results were analyzed by one-way analysis of variance (ANOVA) with 95% confidence level. The analysis was continued with Duncan's Multiple Range Test (DMRT) if there were significant differences between treatments. Statistical analysis using SPSS 25 software. Data is presented in the form of mean ± standard deviation.

## **RESULTS AND DISCUSSION**

The results of microanatomy measurement and description of mice liver in various treatments can be seen in Table 1. Based on the results of ANOVA, the smallest mean hepatocyte diameter was shown in the positive control, which was  $19.23 \pm 0.12 \mu\text{m}$ , and the largest mean hepatocyte diameter was found in the negative control, which was  $21.41 \pm 1.32 \mu\text{m}$ . The mean hepatocyte diameter at extract doses of 150 mg kg<sup>-1</sup> BW, 300 mg kg<sup>-1</sup> BW, and 600 mg kg<sup>-1</sup> BW was not significantly different from the positive control, but significantly different from the extract of 75 mg kg<sup>-1</sup> BW and the negative control (Table 1).

**Table 1.** Measurement results of hepatocyte diameter, sinusoid, and central vein

Treatment	Hepatocyte Diameter ( $\mu\text{m}$ )	Sinusoid Diameter ( $\mu\text{m}$ )	Central Vein Diameter ( $\mu\text{m}$ )
Negative Control	$21.41 \pm 1.32^c$	$1.22 \pm 0.22^a$	$40.69 \pm 1.84^b$
Positive Control	$19.23 \pm 0.12^a$	$4.65 \pm 0.16^e$	$37.51 \pm 1.41^a$
Extract 75 mg kg <sup>-1</sup> BW	$20.55 \pm 0.27^b$	$3.38 \pm 0.24^b$	$38.86 \pm 1.19^{ab}$
Extract 150 mg kg <sup>-1</sup> BW	$19.95 \pm 0.26^{ab}$	$4.09 \pm 0.15^c$	$37.72 \pm 1.20^a$
Extract 300 mg kg <sup>-1</sup> BW	$19.43 \pm 0.15^a$	$4.35 \pm 0.18^{cd}$	$37.14 \pm 2.00^a$
Extract 600 mg kg <sup>-1</sup> BW	$19.50 \pm 0.21^a$	$4.39 \pm 0.23^{de}$	$36.84 \pm 1.79^a$

Data was performed as average ± standard deviation. Different values in the same column showed significant differences (P<0.05)

The largest mean of central vein diameter was found in the negative control, which was  $40.69 \pm 1.84 \mu\text{m}$ , meanwhile, the smallest mean of central vein diameter was found in

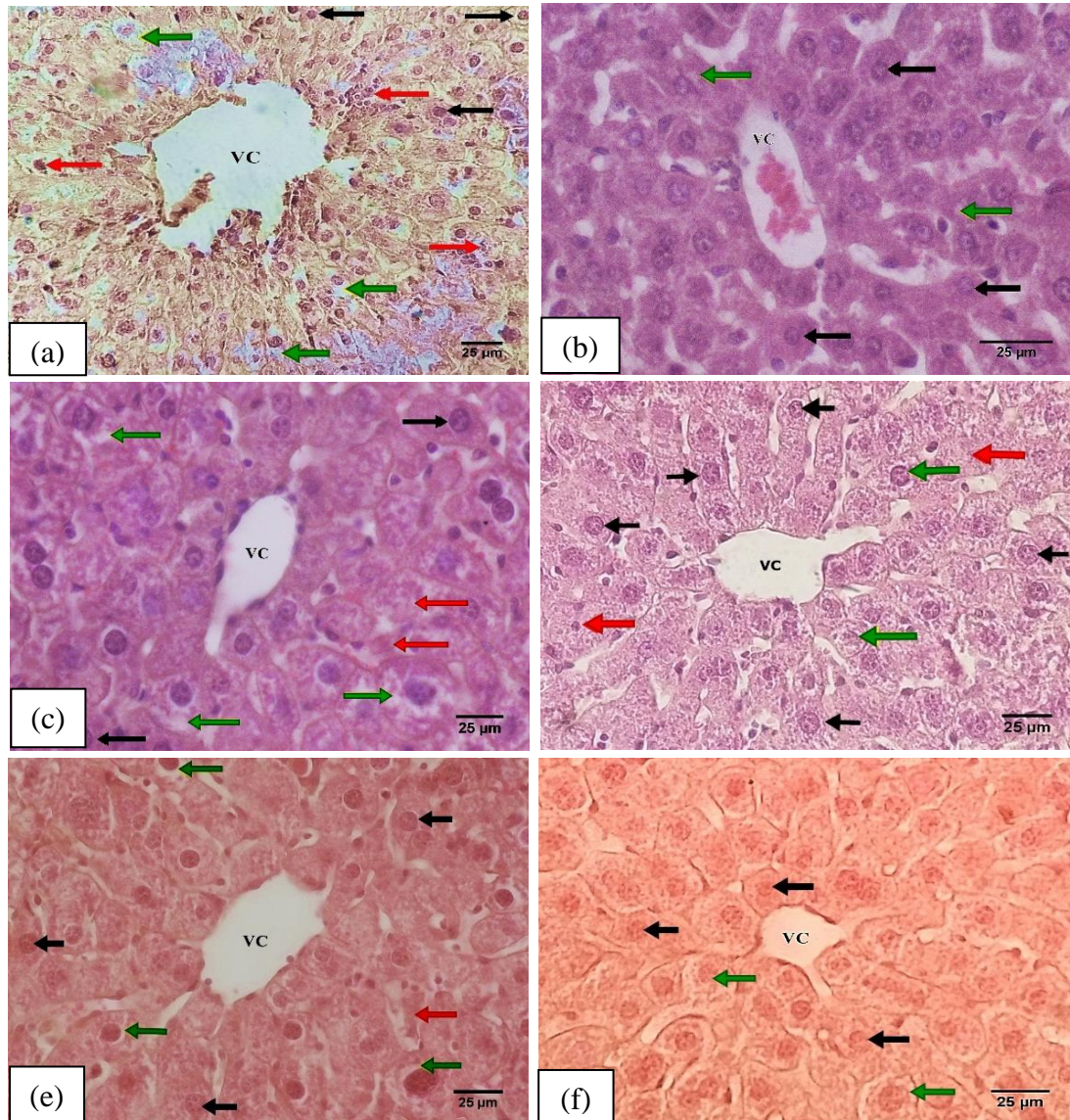
the positive control, which was  $36.84 \pm 1.79 \mu\text{m}$ . The mean central vein diameter in all extract treatments was not significantly different from the positive control ( $p > 0.05$ ) (Table 1).

The result of the sinusoid diameter measurements in every treatment showed that the negative control had the smallest sinusoid diameter compared to the other treatments, at  $1.22 \pm 0.22 \mu\text{m}$  ( $p < 0.05$ ). The largest sinusoid diameter was found in the positive control, which was  $4.65 \pm 0.16 \mu\text{m}$ . The mean diameter of a sinusoid in all extract treatments was relatively the same as the mean diameter of sinusoid negative control (Table 1). The cell swelling affects the increase in hepatocyte diameter. The increase in hepatocyte diameter causes a decrease in sinusoid diameter. The mean diameter of sinusoid positive control and extract treatment at doses of  $150 \text{ mg kg}^{-1} \text{ BW}$ ,  $300 \text{ mg kg}^{-1} \text{ BW}$ , and  $600 \text{ mg kg}^{-1} \text{ BW}$  showed consecutive values of  $4.09 \pm 0.15 \mu\text{m}$ ,  $4.35 \pm 0.18 \mu\text{m}$ , and  $4.39 \pm 0.23 \mu\text{m}$ .

Paracetamol induction at the toxic dose of  $105 \text{ mg kg}^{-1} \text{ BW}$  orally for 7 days caused the mice liver tissue damage indicated by the changes in hepatocyte diameter, sinusoids, and central veins. In the case of paracetamol toxicity, NAPQI radicals will be accumulated in the liver and covalently bind to integral and peripheral proteins on the hepatocyte membrane. The covalent bonds formed can change the structure and function of membrane proteins, including the release of protein linkers which gives impact the decrease in membrane integrity, the damage to the lipid bilayer structure so that it reduces membrane permeability and disrupts the exchange of oxygen and carbon dioxide, the disturbances in transporter proteins, as well as the disturbances in carrier proteins and ion channels which are the basic metabolic pathways in membrane transport systems, both active transport and facilitated passive transport.

The disturbance in active transport begins with the dysfunction of carrier protein. Extracellular  $\text{Na}^+$  ions can form ionic bonds with extracellular  $\text{Cl}^-$  ions, then together diffuse into hepatocytes through ion channels. The concentration of intracellular  $\text{Na}^+$  and  $\text{Cl}^-$  ions will increase. It causes high intracellular osmolarity which can pull the outside water into the hepatocytes (influx) through aquaporin channels. The influx causes hydropic degeneration indicated by water-filled vacuoles in the hepatocytes. The most obvious liver damage was found in the negative control mice. Almost all of the hepatocytes were swollen due to hydropic degeneration (Figure 1a). According to Miller

*et al.* (2017), hydropic degeneration is the most common damage which happens due to hypoxia or exposure to reactive toxins (Figure 1. Green arrow).



**Figure 1.** Mice liver microanatomy (a) negative control (paracetamol 105 mg kg<sup>-1</sup> BW), (b) positive control (Vitamin E 46.8 mg kg<sup>-1</sup> BW), (c) 75 mg kg<sup>-1</sup> BW extract, (d) 150 mg kg<sup>-1</sup> BW extract BW, (e) extract 300 mg kg<sup>-1</sup> BW, and (f) extract 600 mg kg<sup>-1</sup> BW. Normal hepatocytes (black arrows), hydrophilic degenerated hepatocytes (green arrows), necrotizing hepatocytes (red arrows) (400× magnification)

NAPQI radicals that get through the liver sinusoids will be concentrated in the central vein. Continuous toxicant exposure causes endothelial cell damage indicated by the release of endothelial cells from the basement membrane so that the diameter of the

central vein gets wider (Figure 1a). The mean diameter of the central vein in the negative control mice was wider than in the other treatments, which was  $40.69 \pm 1.84 \mu\text{m}$ . The mean diameter of the central vein extract was  $75 \text{ mg kg}^{-1} \text{ BW}$ , not highly different from the negative control. According to several studies, the mice were given standardized feed and had central vein diameters ranging from  $25.86$  to  $81.54 \mu\text{m}$  (Media *et al.*, 2020; Jaber & Al-Bakri, 2018). The statistical data showed that the mean diameter of the central vein in all treatments ranged from  $36.84$  to  $40.69 \mu\text{m}$  (Table 1).

Vitamin E ( $\alpha$ -tocopherol) as the positive control had antioxidant activities. Vitamin E plays a role in donating hydrogen atoms to reactive oxygen molecules resulting in the process of cellular respiration. The OH group on the  $\alpha$ -tocopherol ring linked to the NAPQI radical formed complexes of stable  $\alpha$ -tocopheroxy radicals (Landes, 2005) and inhibited the peroxidation process of hepatocyte biomolecules. Vitamin E administration showed low measurement results of hepatocyte, sinusoid, and central venous diameter in the positive control mice.

The measurement results of hepatocyte, sinusoid, and central vein diameter on laban bark methanol extract treatments at doses of  $150 \text{ mg kg}^{-1} \text{ BW}$ ,  $300 \text{ mg kg}^{-1} \text{ BW}$ , and  $600 \text{ mg kg}^{-1} \text{ BW}$  showed not very different numbers from the positive control. The results of this study are directly proportional to the research of Al-Wajeih *et al.* (2016) regarding the potential of ethanol extract of laban leaves in improving the gastric microanatomical structure of Sprague-Dawley mice with gastritis ulcers caused by ethanol induction. The protection given by both the leaf extract and Laban bark is caused by the presence of flavonoid, saponin, and tannin compounds. The compounds of flavonoid, saponin and tannin in the methanol extract of laban bark are recognized to have antioxidant abilities.

Flavonoids work as antioxidants by donating hydrogen atoms to break the peroxy chain and reduce singlet oxygen. In addition, flavonoids will inhibit the formation of hydroxyl radicals from hydrogen peroxide by chelating ferrous metal ( $\text{Fe}^{2+}$ ) in the Fenton reaction in the body. The tannin compounds play a role as metal chelators, while saponins reduce superoxide radicals through the formation of hydroperoxyls. The hydroxyl group of flavonoids acts as a hydrogen donor to reduce NAPQI radicals. Therefore, flavonoids, saponins and tannins act as antioxidant complexes in reducing NAPQI radicals and

protecting hepatocytes from massive oxidative damage (Simanjuntak, 2012; Treml *et al.*, 2016; Ahmad, *et al.*, 2017).

The attainment of the balance between antioxidants and free radicals in the body allows healthy hepatocytes to be able to proliferate by increasing the mitotic rate of mature hepatocytes and dedifferentiating stem cells into new hepatocytes or cholangiocytes (Esrefuglo, 2013). T

he life span of normal hepatocytes (in humans) is approximately 5 months and they perform cell division at least 68 times with the cell maturation time no later than 1-2 times per year. Safithri (2018) stated that the livers of mice experiencing acute injury were then performed with hepatectomy (2/3 parts), and the remaining 1/3 of the livers were able to regenerate to return to normal mass within 10 days. Based on the results of statistical analysis, the administration of the extract at all dose levels for 7 days began to show various normal hepatocyte regeneration. The extract treatment of 600 mg kg<sup>-1</sup> BW showed the highest mean percentage of normal hepatocytes compared to extract doses of 75 mg kg<sup>-1</sup> BW, 150 mg kg<sup>-1</sup> BW, and 300 mg kg<sup>-1</sup> BW. The mean percentage of normal hepatocytes in the 600 mg kg<sup>-1</sup> BW extract treatment was 70.06±3.67%. These numbers were not significantly different from the mean percentage of normal hepatocytes in the positive control, which was 79.84±1.53%.

## **CONCLUSION**

Based on the results of the study, it can be concluded that the antioxidant compounds of flavonoids, saponins, and tannins in the methanol extract of laban bark were able to improve the microanatomical structure of the liver of mice-paracetamol induced. The optimal dose of extract that showed improvement in liver microanatomy close to the positive control treatment was the extract of 600 mg kg<sup>-1</sup> BW.

## **ACKNOWLEDGMENT**

This research was supported by the Community Development & Outreaching (COMDEV) the University of Tanjungpura Pontianak for Bidikmisi scholarship, Diah Wulandari Rousdy, M.Sc and Dr. Elvi Rusmiyanto Pancaning Wardoyo M.Si who has provided research funding assistance.



## REFERENCES

- Adelina, K., Wardenaar, E., & Sisillia, L. (2014). Kajian etnobotani dan fisiko kimia kulit kayu laban (*Vitex Pubescens* Vahl) di Desa Kape Kecamatan Kapuas Kabupaten Sanggau Kalimantan Barat. *Jurnal Hutan Lestari*, 2(1), 92. doi: <http://dx.doi.org/10.26418/jhl.v2i1.5362>
- Ahmad, A. R., Elya, B., & Mun'im, A. (2017). Antioxidant activity and isolation of xanthine oxidase inhibitor from *Ruellia tuberosa* Linn Leaf. *Pharmacognosy Journal*, 9(5), 607-610 doi: 10.5530/pj.2017.5.96
- Al-Wajeeh, N. S., Halabi, M. F., Hajrezaie, M., Dhiyaaldeen, S. M., Bardi, D. A., Salam, S. M., Rouhollahi, E., Karimian, H., Abdolmalaki, R., Azizan, A. H., Ali, H. M., Noor, S. M., & Abdullah, M. A. (2016). The gastroprotective effect of *Vitex pubescens* leaf extract against ethanol-provoked gastric mucosal damage in Sprague-Dawley rats. *Public Library of Science ONE*, 11(9), 21. <https://doi.org/10.1371/journal.pone.0157431>
- Bunchorntavakul, C., & Reddy, K. R. (2013). Acetaminophen-related hepatotoxicity. *Clinic Liver Disease*, 17(4), 587-607. doi: 10.1016/j.cld.2013.07.005
- Esrefuglo, M. (2013). Role of stem cells in repair of liver injury: Experimental and clinical benefit of transferred stem cells on liver failure. *World Journal Gastroenterology*, 19(40), 6757-6773. doi: 10.3748/wjg.v19.i40.6757
- Garber, J. C., Barbee, R. W., Bielitzki, J. T., Clayton, L. A., Donovan, J. C., Kohn, F. F., Lipman, N. S., Locke, P., Melcher, J., Quimby, F. W., Turner, P. V., Wood, G. A., & Würbel, H. (2011). *Guide for the care and use of laboratory animals*. Washington DC: The National Academies Press.
- Hermansyah, A., Harlia, & Zahara, T. A. (2015). Skrining fitokimia dan uji aktivitas antioksidan ekstrak kulit batang laban (*Vitex pubescens* Vahl). *Jurnal Kimia Khatulistiwa*, 4(2), 67-71. <https://jurnal.untan.ac.id/index.php/jkkmpa/article/view/11735>
- Jaber, N. R., & Al-Bakri, N. A. (2018). Tegretol (Carbamazepine) effect on the morphometric assay of liver in female white mice (*Mus musculus*). *Ibn Al-Haitham Journal for Pure & Applied Science*, 31(3), 6. <https://doi.org/10.30526/31.3.1997>
- Jun, M., Fu, H. Y., Hong, J., Wan, X., Yang, C. S., & Ho, T. (2003). Comparison of antioxidant activities of isoflavones from kudzu root (*Pueraria lobata* Ohwi). *Food Science Technologist*, 68(6), 2117-2122. <https://doi.org/10.1111/j.1365-2621.2003.tb07029.x>
- Jusup, I. (2014). Pengaruh vitamin E dan olahraga terhadap stres oksidatif: Studi pada mencit yang terpapar minyak goreng berulang. *Nutrition and Health*, 2(3).

<https://www.neliti.com/publications/89931/pengaruh-vitamin-e-dan-olahraga-terhadap-stres-oksidatif-studi-pada-mencit-yang>

- Katzung, B. G., Masters, S. B., & Trevor, A.J. (2014). *Basic & clinical pharmacology*, 12th edition, New York: McGraw Hill Medical.
- Makiyah, A., & Khumaisah, L. L. (2018). Studi gambaran histopatologi hepar tikus putih strain Wistar yang diinduksi aspirin pasca pemberian ekstrak etanol umbi iles-iles (*Amorphophallus variabilis* Bl.) selama 7 hari. *Majalah Kedokteran Indonesia*, 50(2), 93-101. <http://dx.doi.org/10.15395/mkb.v50n2.1323>
- Media, N., Rossiana, N., & Malini, D. M. (2020). Toksisitas oil sludge hasil fitoremediasi long term pada histologis hati mencit (*Mus musculus*). *Jurnal Pendidikan dan Biologi*, 12(2), 130-136. <https://doi.org/10.25134/quagga.v12i2.2621>
- Miller, M. A., & Zachary, J. F. (2017). Mechanisms and morphology of cellular injury, adaptation and death. *Pathologic Basis of Veterinary Disease* 19: 2-43. doi: 10.1016/B978-0-323-35775-3.00001-1
- Rousdy, D. W., & Wardoyo, E. R. P. (2018). Efek antioksidan fraksi metanol buah lakum (*Cayratia trifolia* (L.) Domin) terhadap aktivitas enzim superoksida dismutase dan kadar malondialdehid pada mencit stres fisik. Jurusan Biologi Fakultas MIPA Universitas Tanjungpura (Laporan Penelitian).
- Safithri, F. (2018). Mekanisme regenerasi hati secara endogen pada fibrosis hati. Malang: Fakultas Kedokteran Universitas Muhammadiyah.
- Simanjutak, K. (2012). Peran antioksidan flavonoid dalam meningkatkan kesehatan. Jakarta: Bina Widya.
- Suvarna, S. K., Layton, C., & Bancroft, J.D. (ed.). (2013). Bancroft's theory and practice of histological techniques. Churchill Livingstone Elsevier.
- Treml, J., Smejkal, K., Hosek, J., & Zemlicka, M. (2013). Determination of antioxidant activity using oxidative damage to plasmid DNA-pursuit of solvent optimization. *Chemical Papers*, 67(5), 484-489. <https://link.springer.com/article/10.2478/s11696-013-0334-8>
- Wilmana, P. F., & Gan, S. (2012). Analgesik-antipiretik, analgesik antiinflamasi nonsteroid, dan obat gangguan sendi lainnya. Jakarta: Balai Penerbit Fakultas Kedokteran Universitas Indonesia.
- Wulandari, C., Rousdy, D.W., & Wardoyo, E.R.P. (2018). Skrining fitokimia berbagai fraksi ekstrak buah lakum (*Cayratia trifolia* L.). *Jurnal Protobiont*, 7(2), 66-70. <http://dx.doi.org/10.26418/protobiont.v7i2.26641>